

Macro hematoma after micro percutaneous nephrolithotomy: A case report

Renal stone diseases

Aydemir Asdemir¹, Huseyin Saygin², Esat Korgali², Resul Cicek³¹Urology Clinic, Suluova Public Hospital, Amasya²Department of Urology, Faculty of Medicine, Cumhuriyet University, Sivas³Urology Clinic, Malatya Training and Research Hospital, Malatya, Turkey

This article's abstract was presented on 26. Congress of National Urology, on 5. Congress of Urologic Surgery and on 3. Congress of Minimally Invasive Urology.

Abstract

The micropercutaneous nephrolithotomy (mPNL, microperc) method was developed in order to prevent complications. In our clinic, we performed microperc on a 39-year-old man who expelled renal stone. During the microperc procedure, lower pole calyceal access was successfully obtained to get direct access to the stone by using 4.8Fr microperc needle. The patient's hemoglobin dropped from 16.8 to 9.6 gr/dl about 6 hours after surgery. A new computerised tomography (CT) scan demonstrated a large retroperitoneal hematoma measuring 182x97x92 mm. When we performed retroperitoneal exploration, we saw a bleeding area due to the entrance of microperc needle. Then, we controlled the hemorrhage. The patient's hemodynamics remained stable and he did not need any blood transfusion after exploration. Based on this case, it appears reasonable to allow open surgery after microperc to control macro hematoma.

Keywords

Macro; Hematoma; Microperc

DOI: 10.4328/ACAM.20468 Received: 2021-01-06 Accepted: 2021-02-25 Published Online: 2021-03-09 Printed: 2021-08-01 Ann Clin Anal Med 2021;12(8):940-942

Corresponding Author: Aydemir Asdemir, Urology Clinic, Suluova Public Hospital, 05500, Amasya, Turkey.

E-mail: aydemirasdemir@hotmail.com P: +90 5068943216

Corresponding Author ORCID ID: <https://orcid.org/0000-0002-9141-6727>

Introduction

Advances in minimally invasive endourological techniques continue to provide the urologic surgeons with excessive options for the management of symptomatic renal calculi. Reducing the size of instruments in percutaneous nephrolithotomy (PNL) is the so-called 'microperc', in which the procedure is carried out through a 4.8Fr all-seeing needle. Procedural steps of PNL are time-consuming and also may cause complications such as prolonged fluoroscopy times, bleeding through the access tract, infundibular rupture, and pelvic perforation. In order to prevent these complications, the microperc method was developed. But it is not clear how often and which complications occur in all microperc procedures. We reviewed the current literature and reported an index case of coexisting macro hematoma visualized on contrast-enhanced CT after microperc in this case report.

Case Report

A 39-year-old man was admitted to our clinic with left renal lower anteromedial calyceal stone after 3 sessions of extracorporeal shockwave lithotripsy (ESWL) conducted in another clinic. As the patient said, the stone was 1,5cm in diameter before ESWL, and ESWL lasted 2 weeks before he applied to our clinic. We could not contact other clinic and were unable to obtain the patient's documents before ESWL. In our clinical practice, we always talk about flexible ureteroscope, microperc or PNL after one session of ESWL failure. In our clinic, preop computerized tomography (CT) showed us that the stone was single, in lower pole anteromedial calyx, ~12,2x9,4x7,4 mm in size, and its density was 875 HU (Hounsfield unit). After ESWL, the size of the stone decreased, but it was not enough to be subject to clearance spontaneously. We talked about watchful waiting follow-ups if there was no symptom or surgical treatment alternatives, including a flexible ureteroscope or microperc, and their probable complications if symptoms are present. The patient chose treatment because of the pain. In our clinic, we performed left microperc and left ureteral J stent was placed (because of intraoperative overbalance hemorrhage) in this patient. During the microperc procedure, lower pole calyceal access was successfully obtained to reach the stone directly using a 4.8Fr all-seeing microperc needle accompanied by visualization with scopy. No bleeding was observed during the access, and no dilatation was performed. After accessing, we observed that the stone was fragmented into several pieces due to ESWL. A large piece of stone was fragmented with [8 Hertz (6.4 Watt) 0.8 Joule] 200-micron Holmium laser fiber under direct visualization, and all of the pieces were washed out to the ureteropelvic junction. The patient's hemoglobin dropped from 16.8 to 9.6 gr/dl about 6 hours after the operation and he was therefore re-admitted with unstable hemodynamics (heart rate: >100/min and systolic blood pressure: <100 mmHg). Contrast-enhanced CT demonstrated a large retroperitoneal hematoma measuring 182x97x92 mm. Then we consulted the patient with a radiologist if they could make selective embolization and possible drain placement to control the bleeding. But they replied to us they could not because of technical problems. Therefore, we preferred open surgery because of the patient's unstable hemodynamics. When we performed left

retroperitoneal exploration, we observed a huge hematoma and saw a nearly 3-mm bleeding area due to the insertion of a microperc needle into the lower calyceal area of the kidney. Then, we controlled the hemorrhage by suturing this area with 2/0 vicryl and using an absorbable hemostat, involving oxidized cellulose. Also, we positioned a drain here. After the exploration, the patient's hemodynamics and hemoglobin remained stable and he did not need any blood transfusion. Three days after the exploration, patient's drain stopped, we left out his drain and discharged him. These findings confirmed the diagnosis of a macro hematoma after microperc.

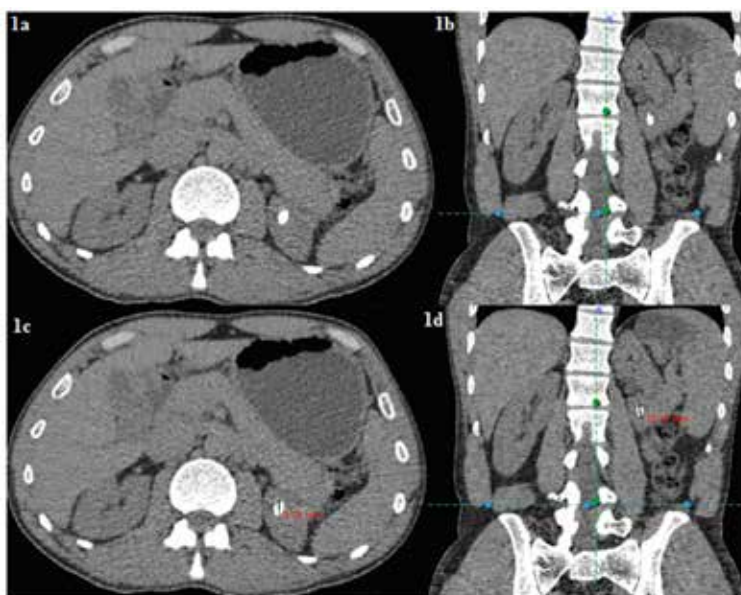


Figure 1. a-d. CT view of preop renal lower pole anteromedial calyceal stone (~12,2x9,4x7,4mm)

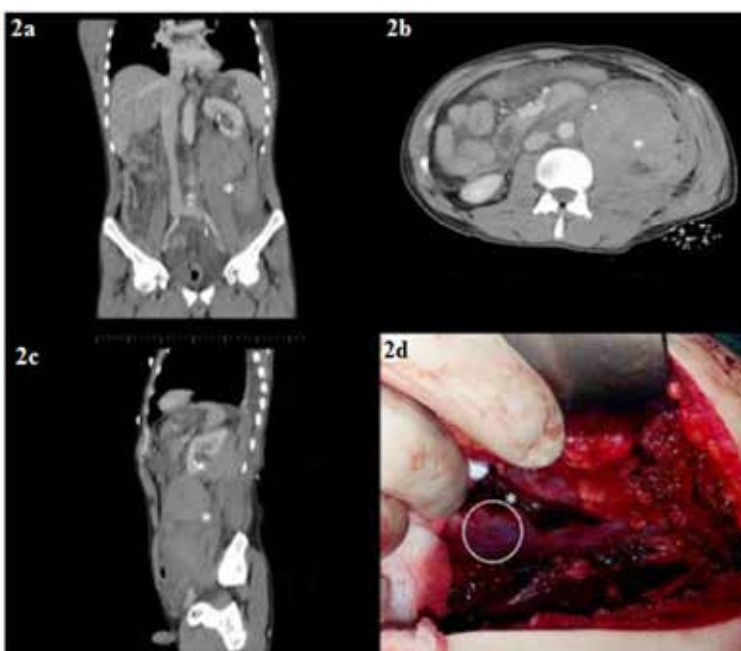


Figure 2a-c. CT view of macro hematoma after microperc.
2d. Exploration image of the needle on the left kidney

Discussion

The aim of performing endoscopic procedures using smaller instruments is to reduce complications rate, morbidity and mortality with no decrease in the success rates. The main limitation of PNL is its invasiveness and accompanying morbidity. Microperc extended the concept of 'All-seeing needle' to perform PNL by using a 4.8-Fr tract [1]. The optical needle helps to avoid any traversing viscera and confirms the visual cues of a correct papilla. This may provide a new standard for obtaining renal access and lithotripsy without dilatation. Complications may develop immediately after the primary puncture; therefore, establishing optimal and atraumatic access to the pelvic system is the most important initial step in a successful PNL procedure [2]. Perinephric hematomas occur in nearly one-third of patients undergoing PNL, but are extensive in only 11% of the cases. Richstone et al., demonstrated the frequency of post-operative hemorrhage following percutaneous renal interventions [3] but this frequency is not clear for microperc. However, there are numerous studies on the success and complications of PNL, and there are a limited number of studies on the success and complications of using microperc. Hatipoglu et al. demonstrated that the mean drop in the hemoglobin level was 0.87 ± 0.84 (0–4.1 g/dL) in their study of 140 patients. Bleeding requiring blood transfusion was observed in only one patient in the present series [4]. The most important advantage of the microperc is reduced bleeding. In microperc, a single-step access under direct visualization helps prevent potential complications during access and dilatation of the tract. It also decreases the risk of intraoperative bleeding. Studies have demonstrated that the size of the nephroscope and tract affects the amount of intraoperative bleeding [5,6]. In the first microperc study, the mean decrease in hemoglobin was found to be 1.4 mg/dL [1] and this study did not report the need for postoperative transfusion [4,5,6].

Conclusion

In summary, only a few published studies have documented the efficacy and safety of microperc. Based on this case, it appears reasonable to allow selective embolization and possible drain placement or open surgery after microperc to control bleeding. It is expected that with a smaller tract, bleeding and complication decrease. However, it is not true for this case, and it is always important to remember that possible important bleeding may occur after microperc procedures ending with selective embolization or exploration.

Scientific Responsibility Statement

The authors declare that they are responsible for the article's scientific content including study design, data collection, analysis and interpretation, writing, some of the main line, or all of the preparation and scientific review of the contents and approval of the final version of the article.

Animal and human rights statement

All procedures performed in this study were in accordance with the ethical standards of the institutional and/or national research committee and with the 1964 Helsinki declaration and its later amendments or comparable ethical standards. No animal or human studies were carried out by the authors for this article.

Conflict of interest

None of the authors received any type of financial support that could be considered potential conflict of interest regarding the manuscript or its submission.

References

- Desai MR, Sharma R, Mishra S, Sabnis RB, Stief C, Bader M. Single-step percutaneous nephrolithotomy (microperc): the initial clinical report. *J Urol*. 2011;186(1):140–5.
- Chan YH, Wong KM, Kwok PC, Liu AY, Choi KS, Chau KF, et al. A veno-caliceal fistula related to ureteric stricture in a kidney allograft masquerading as renal failure. *Am J Kidney Dis*. 2007;49(4):547–51.
- Chichakli R, Krause R, Voelzke B, Turk T. Incidence of perinephric hematoma after percutaneous nephrolithotomy. *J Endourol*. 2008;22(6):1227–32.
- Hatipoglu NK, Tepeler A, Buldu I, Atis G, Bodakci MN, Sancaktutar AA, et al. Initial experience of micro-percutaneous nephrolithotomy in the treatment of renal calculi in 140 renal units. *Urolithiasis*. 2014;42(2):159–64.
- Kukreja R, Desai M, Patel S, Bapat S. Factors affecting blood loss during percutaneous nephrolithotomy: prospective study. *J Endourol*. 2004;18(8):715–22.
- Unsal A, Resorlu B, Kara C, Bozkurt OF, Ozyuvali E. Safety and efficacy of percutaneous nephrolithotomy in infants, preschool age, and older children with different sizes of instruments. *Urology*. 2010;76(1):247–52.

How to cite this article:

Aydemir Asdemir, Huseyin Saygin, Esat Korgali, Resul Cicek. Macro hematoma after micro percutaneous nephrolithotomy: A case report. *Ann Clin Anal Med* 2021;12(8):940–942